

## SPONTANEOUS TOXOPLASMOSIS IN THE GUINEA-PIG IN PANAMA

ENID DE RODANICHE AND TERESINA DE PINZON

Department of Public Health, Panama, R. P., and Gorgas Memorial Laboratory,  
Panama, R. P.

Although toxoplasmosis has been identified in man and a wide variety of birds and mammals in various parts of the world, it was not until 1943 that its occurrence was first noted on the Isthmus of Panama. In that year Johnson described an epidemic of toxoplasmosis in Army carrier pigeons in the Canal Zone. These birds, however, represented imported stock and may have been infected at the time of introduction. A chronic form of this infection in pigeons has been demonstrated by Manwell and coworkers (1945). Recently, Kean and Grocott (1948) studied a case of congenital toxoplasmosis in a Panamanian infant and referred to 5 cases of asymptomatic infection with this organism observed by them in the Panama Area. These same authors (1945) in an earlier report of a case of probable sarcosporidiosis in a 48 year old Jamaican-born woman noted parasites in 5 of 60 laboratory guinea-pigs but were uncertain whether to classify them as sarcosporidia or toxoplasma. However, these animals also were recent importations from the States, where spontaneous toxoplasmosis in stock experimental guinea-pigs has been demonstrated by Sabin and Olitsky (1937) and Markham (1937).

During the course of studies of Q fever in the Gorgas Memorial Laboratory we observed spontaneous toxoplasmosis in guinea-pigs established in this area and without contact with recently imported members of their species. We feel that this finding is of especial interest from the epidemiological standpoint as guinea-pigs are frequently maintained as pets or as sources of food in homes both in the city and in rural areas where they come into intimate contact with human beings and domestic animals.

Due to the failure of other sources the Gorgas Memorial Laboratory recently was obliged to purchase guinea-pigs from native dealers who collect them from small breeders in the environs of the City of Panama and in the Interior of the Republic. One batch of 8 pigs purchased in the neighborhood of Panama Vieja on the outskirts of the city was noted to be of exceptionally poor quality, thin and sluggish with yellowish staring coat. One of these animals was found moribund the day after arrival. Post-mortem examination failed to reveal marked gross pathology but numerous toxoplasma were observed in Giemsa-stained impression smears of the liver, spleen, lung and peritoneal wall. Culture of the heart blood yielded colonies of gram-positive green-producing diplococci.

An emulsion of the spleen and part of the liver of this animal was used to inoculate intraperitoneally 2 mice which died in 24 hours. One was discarded due to advanced decomposition. Smears of the various organs of the other including spleen, liver, lung, brain, kidney, testicle and heart revealed large numbers of free and intracellular toxoplasma as well as overwhelming septicemia by gram-positive diplococci. An attempt to passage this strain to other guinea-pigs and mice was made by the simultaneous administration of sulfathiazole to control the bacterial in-

fection. However, we failed to find toxoplasma in animals sacrificed 1 to 3 weeks after injection. In this connection we may note that Sabin and Warren (1941) and Weinman and Berne (1944) have noted a marked prophylactic effect of the sulfonamide compounds against experimental toxoplasma infections in mice.

The remaining 7 guinea-pigs in the afore-mentioned batch improved in general condition and were later pressed into use for experimental work with *Rickettsia burneti*. Histological examination of these animals at the time of death or sacrifice revealed very light infection with toxoplasma in two. Attempts at further passage by the intraperitoneal route in adult and 10 day old guinea-pigs and adult white mice resulted in reproduction of the typical clinical syndrome of Q fever but in diminution in numbers or disappearance of the toxoplasma. Especially careful check was made of stained smears and serial sections of the various organs of these animals, as Mooser in 1929 and more recently Perrin and coworkers (1943) found that infections with toxoplasma complicated their studies of typhus in the guinea-pig. Subsequent purchases of guinea-pigs from other localities have revealed only one further toxoplasmic infection up to the present time.

Morphologically the toxoplasma observed by us correspond closely to the excellent descriptions of Wolf, Cowen and Paige (1940) and Guinarães (1943).

In Giemsa-stained contact smears these protozoons are readily identified (See Plate I). They are usually crescentic in shape with pointed or rounded ends, from 4 to 8  $\mu$  in length by 1.5 to 3  $\mu$  in width. The cytoplasm stains blue and the nucleus which is usually subterminal or terminal in position, round or band-shaped, stains a reddish purple. They may be observed free in the tissue fluid, in the act of penetrating the large mononuclear cells or in the intracellular position. Several may be observed penetrating the same cell simultaneously. In smears prepared several hours after the death of the animal the majority of toxoplasma were seen as shortened, thickened, oval, sharply defined forms with a vacuolated irregularly staining blue cytoplasm and no definite nucleus. These were considered to be degenerative forms. In paraffin-sections stained with hematoxylin-eosin, free forms were more difficult to identify but were occasionally noted in the sinuses of the liver and spleen. Intracellular clusters of the parasites or cysts, however, containing varying numbers of small organisms were readily observed. Where the number of intracellular organisms was few, a layer of cytoplasm usually surrounded each nucleus. But in cysts containing numerous organisms, the nuclei apparently were embedded in a syncytium. Toxoplasma were found in smears or sections of the liver, spleen, lungs, testicles, peritoneal wall, brain, kidney and heart. They were most abundantly present, however, in the liver, lungs and peritoneal wall.

#### PATHOGENICITY

We were unable to obtain any evidence of pathogenicity for this strain of toxoplasma by the intraperitoneal route of inoculation in either guinea-pigs or mice. Where symptoms or gross pathology was observed, there was always an associated infection with the diplococcus previously mentioned or with *R. burneti*. The animals employed may have possessed a certain degree of immunity. However, 10 day old guinea-pigs proved equally as resistant as older pigs. Infant mice were not available. The great abundance of toxoplasma noted in smears of animals dying of the diplococcal infection is of interest. Evidently this infection so reduced the natural re-

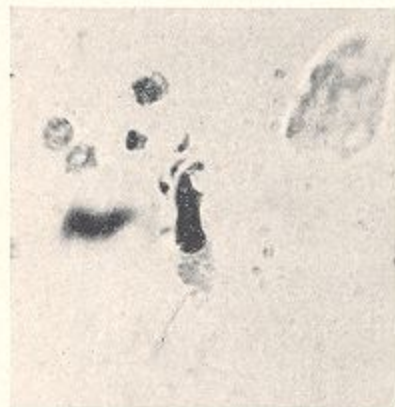


FIG. 1.

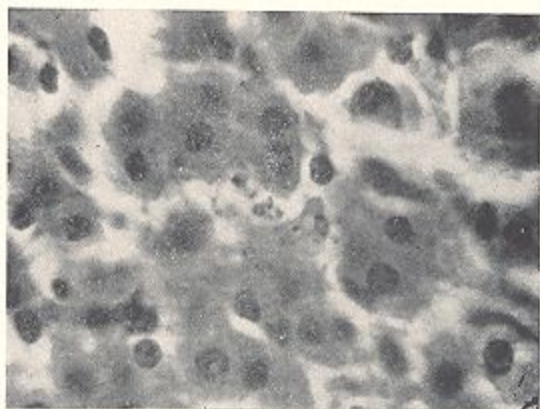


FIG. 4.

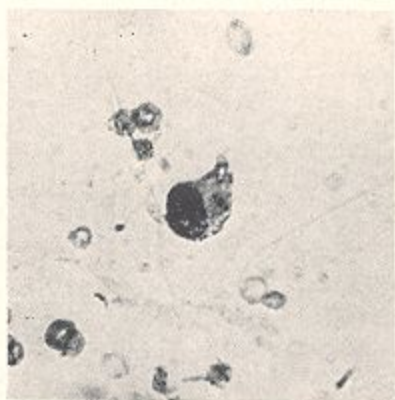


FIG. 2.

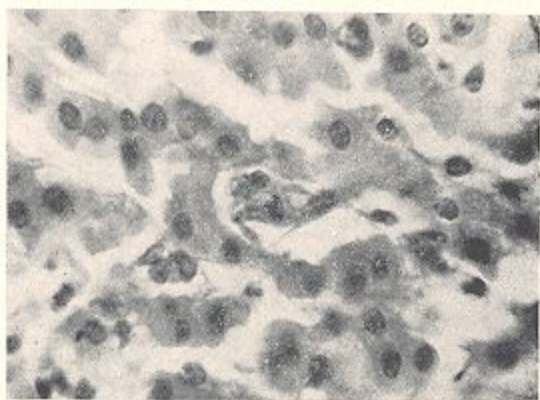


FIG. 5.

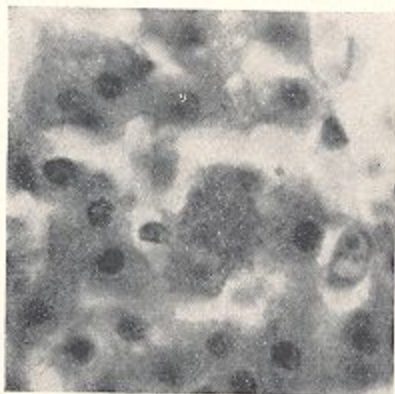


FIG. 3.

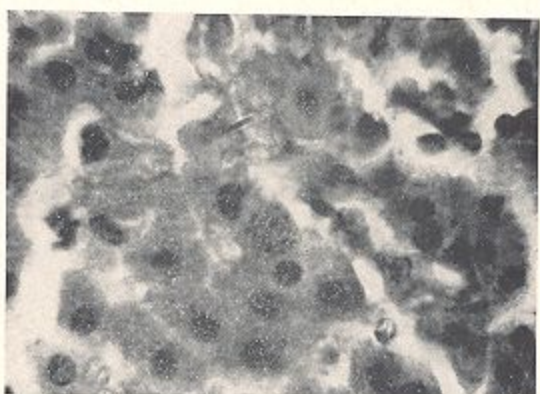


FIG. 6.

## PLATE I

Contact smear of testicle of guinea-pig. Giemsa.  $\times 720$ .

FIG. 1. Extracellular toxoplasma.

FIG. 2. Cluster of three intracellular toxoplasma. One free parasite.

Paraffin section of liver of guinea-pig. Hematoxylin and Eosin.  $\times 720$ .

FIG. 3. Large cyst.

FIG. 4. Toxoplasma free in sinus and invading contiguous cells.

FIG. 5. Small cluster of intracellular parasites.

FIG. 6. Small cyst.

sistance of the animals as to permit rapid multiplication and widespread invasion by these protozoons.

#### CONCLUSION

Spontaneous infection with toxoplasma was observed in guinea-pigs purchased in the suburbs of the city of Panama, and representing stock established in this area and without contact with recently imported members of their species.

#### REFERENCES

- GUIMARÃES, F. N. 1943 Toxoplasmose humana. Meningoencefalomielite toxoplasmica. *Memorias Instituto Oswaldo Cruz* **38**: 257-320.
- JOHNSON, C. M. 1944 Annual Report of the Gorgas Memorial Laboratory, 1943 pp. 15-16. Government Printing Office, Wash., D. C.
- KEAN, B. H. AND GROCOTT, R. G. 1945 Sarcosporidiosis or Toxoplasmosis in Man and Guinea Pig. *Am. J. Path.* **21**: 467-483.
- 1948 Congenital Toxoplasmosis. *J. Amer. Med. Ass.* **136**: 104-108.
- MANWELL, R. D., COULSTON, F., BINCKLEY, E. C. AND JONES, VIRGINIA. 1945 Mammalian and Avian Toxoplasmosis. *J. Infec. Dis.* **76**: 1-14.
- MARKHAM, F. S. 1937 Spontaneous Toxoplasma Encephalitis in the Guinea Pig. *Amer. J. Hyg.* **26**: 193-196.
- MOOSER, H. 1929 Tabardillo, an American variety of Typhus. *J. Infec. Dis.* **44**: 186-193.
- PERRIN, T. L., BRIGHAM, G. D. AND PECKENS, E. C. 1943 Toxoplasmosis in Wild Rats. *J. Infec. Dis.* **72**: 91-96.
- SABIN, A. B. AND OLITSKY, P. K. 1937 Toxoplasma and Obligate Intracellular Parasitism. *Science* **85**: 336-338.
- AND WARREN, JOEL. 1941 Therapeutic Effect of the Sulfonamides on Infection by an Intracellular Protozoon (Toxoplasma). *J. Bacteriol.* **41**: 80.
- WEINMAN, D. AND BERNE, R. 1944 Therapeutic Cure of Acute Experimental Toxoplasmosis in Animals. *J. Amer. Med. Ass.* **124**: 6-8.
- WOLF, A., COWEN, D. AND PAIGE, BERYL. 1940 Toxoplasmic Encephalomyelitis. IV. Experimental Transmission of the Infection to Animals from a Human Infant. *J. Exper. Med.* **71**: 187-214.